



## Coronary artery spasm – one medical entity with different treatment options

Spazam koronarne arterije – jedan medicinski entitet sa različitim terapijskim opcijama

Vladimir Zdravković\*<sup>†</sup>, Rada Vučić\*<sup>†</sup>, Miodrag Srećković\*<sup>†</sup>, Ivan Simić\*<sup>†</sup>,  
Vojislav Mitrović<sup>‡</sup>, Dragan Dinčić<sup>§||</sup>, Slavko Knežević<sup>||</sup>, Nemanja Zdravković\*\*

University of Kragujevac, \*Faculty of Medical Sciences, Kragujevac, Serbia; Clinical Center Kragujevac, <sup>†</sup>Department of Cardiology, <sup>||</sup>Department of Internal Medicine, Kragujevac, Serbia; Klinikum Coburg, GmbH, <sup>‡</sup>Department of Cardiology, Coburg, Germany; <sup>§</sup>Military Medical Academy, Belgrade, Serbia; University of Defence, <sup>||</sup>Faculty of Medicine of the Military Medical Academy, Belgrade, Serbia; University of Kragujevac, Faculty of Medical Sciences, \*\*Center for Molecular Medicine and Stem Cell Research, Kragujevac, Serbia

### Abstract

**Introduction.** Myocardial infarction (MI) is characterized by a critical myocardial ischemia followed by an irreversible myocardial cell damage or death. **Case report.** We presented two similar clinical cases with the ST segment elevation myocardial infarction (STEMI) diagnosis due to a prolonged coronary artery spasm, but with different treatment options due to different basic pathophysiological substrates and clinical presentations. **Conclusion.** Coronary artery spasm is a very complex pathophysiological entity with a different medication therapy management. Although the percutaneous coronary intervention can be the first choice, the treatment strategy should be carefully planned.

**Key words:** myocardial infarction; coronary vasospasm; therapeutics; verapamil; angioplasty, transluminal, percutaneous, coronary.

### Apstrakt

**Uvod.** Infarkt miokarda se karakteriše kritičnom ishemijom miokarda praćenom ireverzibilnim oštećenjem ili smrću ćelija. **Prikazi bolesnika.** Prikazali smo dva slična klinička slučaja bolesnika sa dijagnozom infarkta miokarda sa elevacijom ST segmenta (STEMI), oba sa vazospazmom koronarnih arterija, ali sa različitim terapijskim pristupom, zbog različitih osnovnih patofizioloških supstrata i kliničkih prezentacija. **Zaključak.** Spazam koronarne arterije je veoma kompleksan patofiziološki entitet, sa različitim terapijskim opcijama. Iako perkutana koronarna intervencija može biti prvi izbor, strategija lečenja ipak treba da bude pažljivo isplanirana.

**Ključne reči:** infarkt miokarda; aa.coronariae, spazam; lečenje; verapamil; angioplastika, tanslumenska, perkutana, koronarna.

### Introduction

Myocardial infarction (MI) occurs when myocardial ischemia exceeds a critical threshold and overwhelms myocardial cellular repair mechanisms designed to maintain a normal operating function and homeostasis. Critical myocardial ischemia results in an irreversible myocardial cell damage or death. It can occur as a result of increased myocardial metabolic demand, decreased delivery of oxygen

and nutrients to the myocardium via coronary circulation, or both. MI can be subcategorized on the basis of anatomic, morphologic, and diagnostic clinical information. A new definition can classify acute MI by a clinical scenario into the various subtypes (1–5 types). Type 2 is secondary to the ischemia from a supply-and-demand mismatch. Coronary artery spasm is one possibility and sometimes is an unrecognized and undiagnosed cause of MI<sup>1</sup>. Coronary angiogram shows the

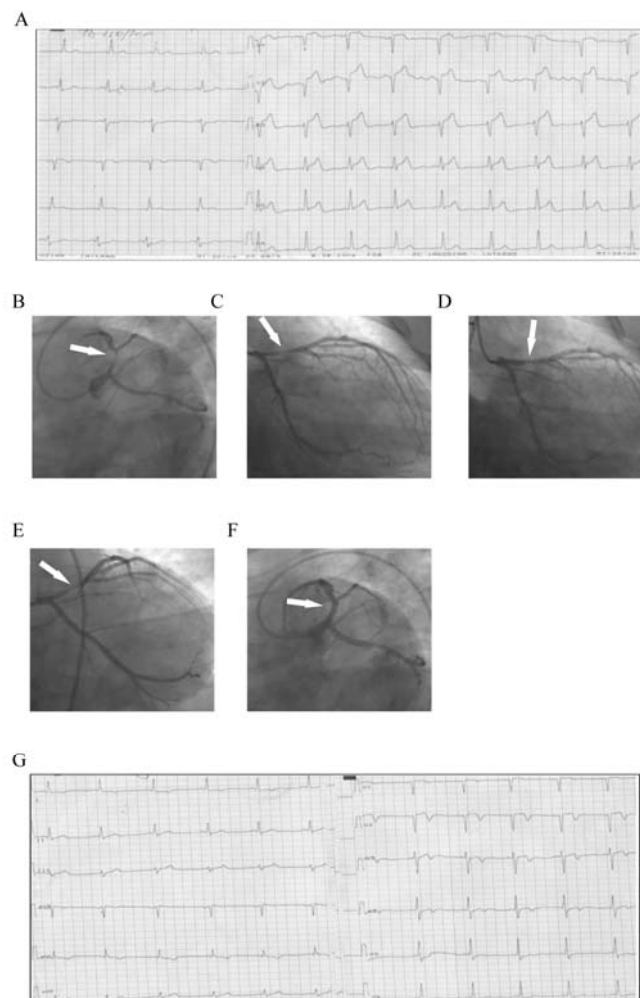
state of vasculature at the time of the exam, and the stenosis absence does not necessarily mean the disease absence.

We presented two similar clinical scenarios in which both patients suffered from the myocardial necrosis due to a prolonged coronary artery spasm, but with the completely different treatment options.

### Case report 1

A 39-year-old male was admitted to the regional hospital with ECG abnormalities, which included ST segment elevation in precordial leads [ST segment elevation myocardial infarction (STEMI) of anterior wall]. Therefore, thrombolytic therapy was prescribed resulting in the clinical, laboratory and ECG signs of reperfusion. However, five days later, he experienced the chest pain followed by the ST segment elevation in precordial leads (reSTEMI of anterior wall) (Figure 1A). Taking everything into account, the patient was immediately transferred to our hospital due to the necessity of primary percutaneous coronary intervention (PCI).

At the admission he breathed normally, with the rhythmic heart beats and normal blood pressure (130/80 mmHg). Coronary angiography was performed and a subocclusive (99%) lesion in proximal left anterior descending (LAD) artery was visualized (Figures 1B and C). Circumflex branch of the left coronary artery (LCA) and right coronary artery (RCA) were without a significant stenosis. After intracoronary (i.c.) administration of nitroglycerin (NTG), the subocclusive stenosis in LAD turned into 30%, which indicated a spasm (Figure 1D). At this point, the ECG changes were in regression. However, five minutes later, angiogram showed the progression of the stenosis up to 80% (Figure 1E) with the chest discomfort and the ST reelevation in the precordial leads. I.C. administration of NTG was repeated, as well as verapamil i.c. application, but the same thing happened again. Therefore, we decided to stent the lesion. Resolute Integrity  $3.5 \times 15$  mm was implanted up to 16 atm from the ostium of LAD (Figure 1F). After the procedure, the patient was asymptomatic and ECG showed absence of ST segment elevations with the T waves inversion in precordial leads (Figure 1G).

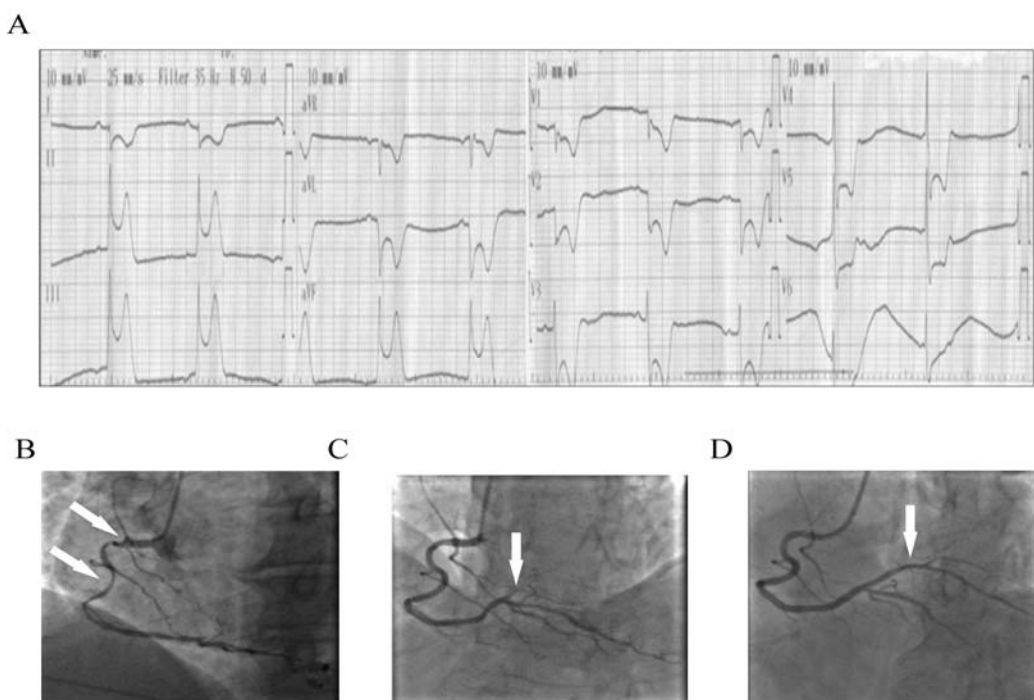


**Fig. 1 – A) ECG: ST elevation in precordial leads (V1-V5); B) left anterior oblique (LAO) caudal: subocclusive proximal left anterior descending (LAD) lesion; C) right anterior oblique (RAO) caudal: subocclusive proximal LAD lesion; D) After intracoronary (i.c.) nitroglycerin (NTG) bolus, only 30% of residual stenosis present; E) Few minutes after NTG was given, severe stenosis in LAD occurred again; F) Final result, after stent implantation in LAD; G) ECG: T waves inversion in precordial leads (V1-V5).**

### Case report 2

A 49-year-old male was admitted to the Cardiology Department due to MI, presented with the chest pain and nausea two hours before the admission. His previous medical records indicated the coronary artery disease diagnosed by coronary angiography a few months before the admission (borderline stenosis in LAD). At the admission, the patient was pale, with slow heart rate and low blood pressure (95/60 mmHg). ECG showed the ST segment elevations in the inferior leads (STEMI of the inferior wall) and the sinus rhythm but along with an occasional occurrence of the third-degree AV block (Figure 2A). The coronary angiography showed LCA with no significant stenosis as well as the RCA with a significant spasm in the proximal and medial part along with

the occlusion of the posterolateral branch (PL) (Figure 2B). After the intracoronary administration of NTG, the spasm in the RCA disappeared (Figure 2C) which resulted in a significant hemodynamic improvement of the patient. However, the patient still had a serious chest pain and closed PL branch (Figure 2C). Our decision was to repeat i.c. administration of the NTG, but nothing has changed. The PL branch was still occluded and it seemed that we needed to continue with the PCI. However, we decided to inject verapamil i.c. and after the second bolus the PL branch appeared all the way (Figure 2D). The angiogram performed 20 minutes later revealed a normal RCA system, while the ECG showed the absence of the ST elevations in the inferior leads with the T waves inversion in lateral leads.



**Fig. 2 – A) ECG: ST elevation in inferior leads (II, III, aVF) with ST depression in anterolateral leads (V1-V6, I, aVL); B) right coronary artery (RCA) with spasm in proximal and medial part; occlusion of the posterolateral branch (PL); C) After nitroglycerin (NTG) administration, normal luminogram of RCA, PL branch occluded; D) After verapamil administration, normal luminogram of RCA, PL branch appeared.**

### Discussion

MI is characterized by an interruption in the supply of the myocardial oxygen and nutrients. Mostly, it occurs when a thrombus is superimposed over an ulcerated or unstable atherosclerotic plaque, thus resulting in a high grade (> 75%) fixed coronary artery stenosis or coronary occlusion. But, the limited supply of oxygen and nutrients in MI can also be caused by a dynamic stenosis associated with the prolonged coronary vasospasm. In both situations, there will be clinical, electrocardiographical and laboratory abnormalities indicating acute MI, but the pathophysiological mechanisms are different<sup>1</sup>.

As it was revealed in the CASPAR study, most patients (98.5%) with the STEMI had the culprit lesions as an

underlying cause of STEMI, but only 41.3% of the patients suffering from an unstable angina had culprit lesions<sup>2</sup>. In the first case, pathophysiologic mechanisms on the atherosclerotic plaque surface, including the release of local vasoconstrictors, triggered the acute coronary syndrome (ACS). A small erosion or fissure plaque surface releases the potent thrombogenic material and vasoconstrictors as well as platelet-derived factors and thrombin<sup>3</sup>. Clinical presentation is ACS (STEMI in case of coronary artery occlusion) followed by the ECG and laboratory abnormalities. It requires a careful decision in terms of treatment. Lesions, presumably responsible for the acute ischemic event, have only mild to moderate stenosis<sup>4</sup>. Plaque rupture with its consequent thrombus formation and local vasospasm should be taken in-

to consideration for the PCI. In our first case, intracoronary administration of verapamil and NTG stenosis turned to 30%, but not for a long time, because locally released vasoconstrictors from the ruptured plaque seriously endangered the patient. Our patient had clinical presentation of STEMI five days before the admission, and was treated with thrombolytic therapy. The patient responded well and the ST elevation vanished. But five days after that, reSTEMI occurred and the coronary angiography was performed. Since there was no response to the intracoronary NTG and verapamil, we treated the culprit lesion with the PCI, risking the spasm occurrence below the stent. Three months later, we repeated the coronary angiography and the spasm occurred in the long segment of the radial artery (Figure 1A). It was resolved with the NTG. The coronary angiogram was normal, without restenosis in stent or in segment (Figures 1B and C), and also without any presence of spasm in the coronary arteries. The patient had no chest pain or ECG abnormalities.

The long term treatment included cardioselective beta adrenergic blockers, whose benefit is well established, although mostly from the trials pre-dating the advent of the modern reperfusion therapy and pharmacotherapy<sup>5,6</sup>.

In the second case, prolonged vasospasm was the key role abnormality responsible for ACS. The awareness and knowledge of coronary artery spasm and its pathophysiology has a great importance for a cardiologist who deals with the ACS patients. Angiographically normal coronary arteries occur in 25% of the patients with the ACS<sup>2</sup>. Related to that, as it was revealed in the CASPAR study, only 1.5% of the patients with STEMI have no culprit lesions (e.g. ruptured plaque) as an underlying cause of STEMI<sup>2</sup>. There are varieties of mechanisms responsible for the coronary spasm: endothelial dysfunction, primary hyperreactivity of vascular smooth muscle cells (VSMCs), and other factors (clinical risk factors, inflammation, ethnic influences)<sup>3</sup>. Endothelial dysfunction might impair the endothelium-mediated vasodilatation (mostly, higher prevalence of mutations of NO synthase gene) and can favor coronary artery spasm in response to the vasoconstrictors at the site of the predisposed segments<sup>7</sup>. In patients with the variant angina, coronary artery spasm can be elicited by the several stimuli that act through different receptors and cellular mechanisms, responsible for the hyperreactivity. One of the mechanisms of VSMC hyperreactivity is represented by an increase in Rho-kinase activity<sup>8</sup>. Mast cells, accumulated predominantly in the adventitia, can activate matrix metalloproteinase and release vasoconstrictors (especially histamine), causing ACS<sup>9,10</sup>. Among the potential triggers of coronary artery spasm, the autonomic nervous system (i.e. an increase in sympathetic

and parasympathetic tone) has received a great deal of attention. But, the trigger could also be an abnormal platelet activation [releasing large amounts of vasoconstrictor substances, including thromboxane A<sub>2</sub> (TXA<sub>2</sub>) and serotonin], an increased release of the powerful vasoconstrictor endothelin-1 (ET-1) by endothelial cells, or hyperventilation (increasing arterial pH, which leads to an increased intracellular calcium influx)<sup>3</sup>. Coronary vasospasm form – variant angina, mostly occurring in the early morning. There is an association with the circadian variation of an increased tonus of the epicardial coronary artery in the early morning and the decreased one in the afternoon<sup>4</sup>. In this case, the prolonged variant angina caused the necrosis of the myocardial cells. The medicament treatment should be the key for these patients, as it was in our second case. Calcium-channel blockers seem to be the established therapy for the coronary artery spasm, and the decrease in the frequency of the variant angina is attributed to the widespread use of these drugs. Long-acting nitrates were also found to be efficient, and their vasodilatory effect may be the additive to the calcium antagonists. Magnesium deficiency is a possible factor contributing to the coronary artery spasm, and its long-term supplementation might also have a preventive effect<sup>11</sup>.

In our case, the coronary angiography showed no stenosis or lesions in the RCA after the i.c. administration of verapamil. We decided to perform an optimal medicament treatment.

Six months later, the patient had no chest pain or ECG abnormalities.

### Conclusion

These two cases illustrate that there is no unique solution for resolving the coronary vasospasm, thus requiring additional caution in practice. The unstable atherosclerotic plaque associated with STEMI is more frequent, thus the invasive strategy with stent implantation certainly has the priority. The above mentioned also includes the additional invasive diagnostic (e.g. intravascular ultrasound, optical coherence tomography) whenever possible. Anyway, the operator has to be patient and tactful and sometimes should try the less invasive treatment which has significantly fewer complications.

### Acknowledgement

We would like to thank Jelena Zdravković and Marija Zdravković for the language revision of the manuscript.

### R E F E R E N C E S

1. Thygesen K, Alpert JS, White HD. Universal Definition of Myocardial Infarction. *J Am Coll Cardiol* 2007; 50(22): 2173–95.
2. Ong P, Athanasiadis A, Hill S, Vogelsberg H, Voelbringer M, Sechtem U. Coronary Artery Spasm as a Frequent Cause of Acute Coronary Syndrome. The CASPAR (Coronary Artery Spasm
3. Lanza GA, Carreri G, Crea F. Mechanisms of Coronary Artery Spasm. *Circulation* 2011; 124(16): 1774–82.

4. Wang LX, Lü SZ, Zhang WJ, Song XT, Chen H, Zhang LJ. Coronary spasm, a pathogenic trigger of vulnerable plaque rupture. *Chin Med J* 2011; 124(23): 4071–8.
5. Steg G, James SK, Atar D, Badano LP, Blomstrom-Lundqvist C, Borger MA, et al. ESC Guidelines for the management of acute myocardial infarction in patients presenting with ST-segment elevation. *Eur Heart J* 2012; 33(20): 2569–619.
6. Giacoppo D, Baber U, Mehran R. Current developments in dual antiplatelet therapy after stenting. *Minerva Cardioangiologica* 2014; 62(3): 261–76.
7. Kaneda H, Taguchi J, Kuvada Y, Hangaishi, Aizawa T, Yamakado M, et al. Coronary artery spasm and the polymorphisms of the endothelial nitric oxide synthase gene. *Circ J* 2006; 70(4): 409–13.
8. Kandabashi T, Shimokawa H, Miyata K, Kunibiro I, Kawano Y, Fukata Y, et al. Inhibition of myosin phosphatase by upregulated Rho-kinase plays a key role for coronary artery spasm in a porcine model with interleukin-1beta. *Circulation* 2000; 101(11): 1319–23.
9. Otsuka F, Sakakura S, Virmani R. Are mast cells the real culprit in atherosclerosis? *Eur Heart J* 2013; 34(48): 3681–3.
10. Zdravkovic V, Pantovic S, Rosic G, Tomic Lucic A, Zdravkovic N, Colic M, et al. Histamine Blood Concentration in Ischemic Heart Disease Patients. *J Biomed Biotechnol* 2011; 2011: 315709.
11. Teragawa H, Kato M, Yamagata T, Matsuura H, Kajiyama G. The preventive effect of magnesium on coronary spasm in patients with vasospastic angina. *Chest* 2000; 118(6): 1690–5.

Received on April 5, 2016.

Revised on December 12, 2016.

Accepted on December 14, 2016.

Online First December, 2016.